

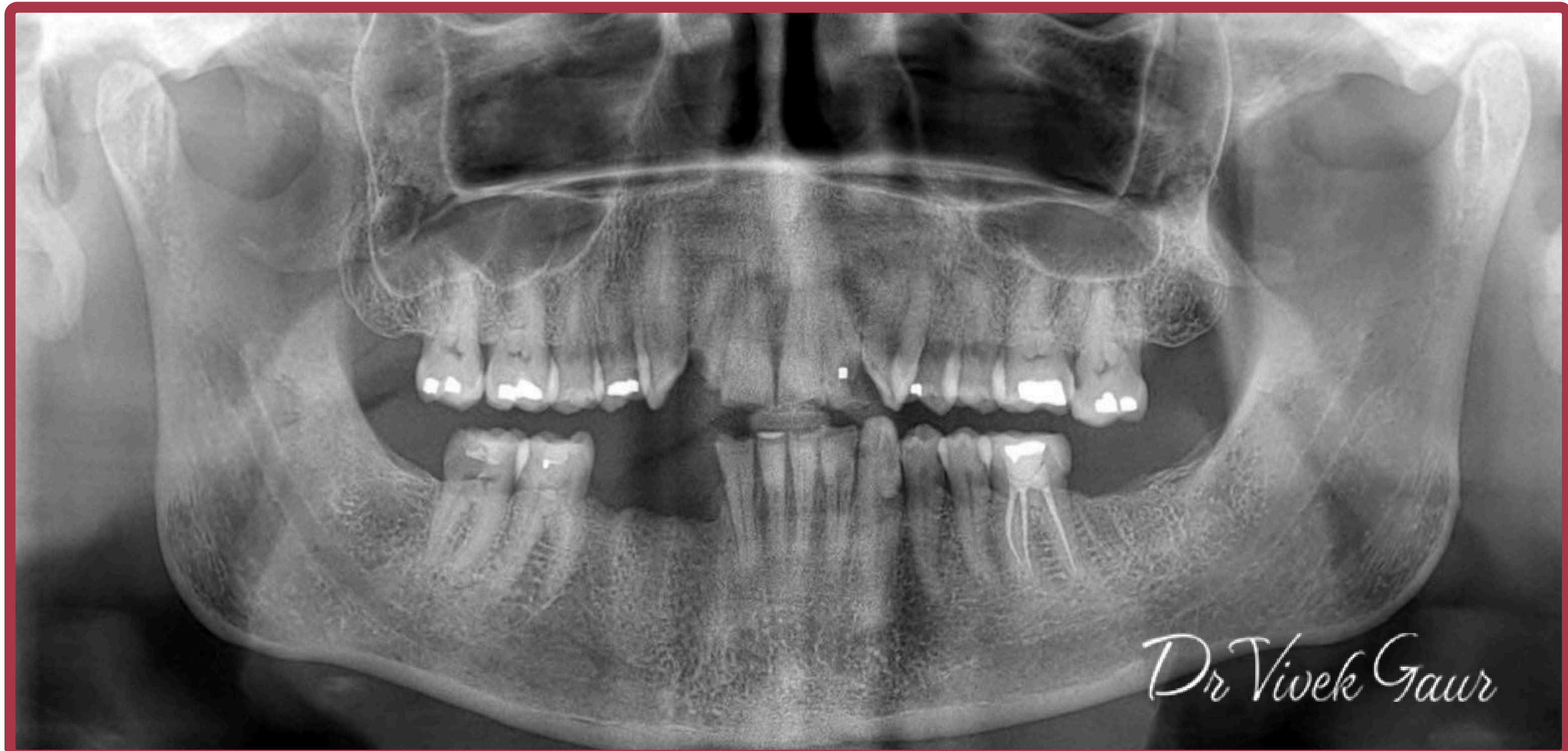Dr Vivek Gaur

A patient from the USA required a swift solution and underwent full-mouth rehabilitation using the immediate functional loading protocol. The patient presented with generalized caries and brittle teeth, frequently experiencing fractures and chipping. The treatment involved the immediate extraction of teeth, followed by the placement of **Corticobasal® Implants**. The entire case was completed in just 2 days, with final full-ceramic restorations.

www.drivivekgaur.com

Dr Vivek Gaur

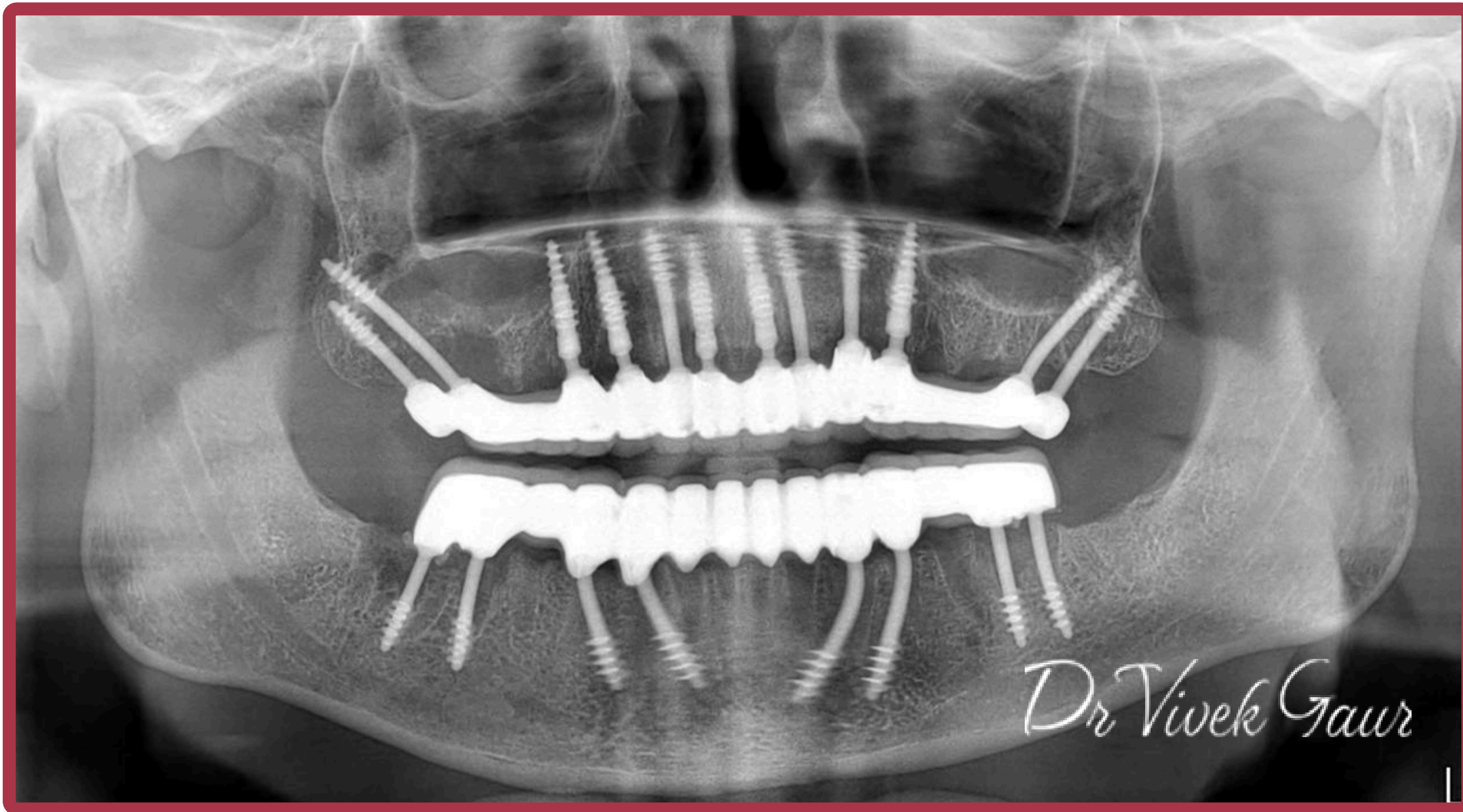
Pre-op XRAY



www.drivivekgaur.com

Dr Vivek Gaur

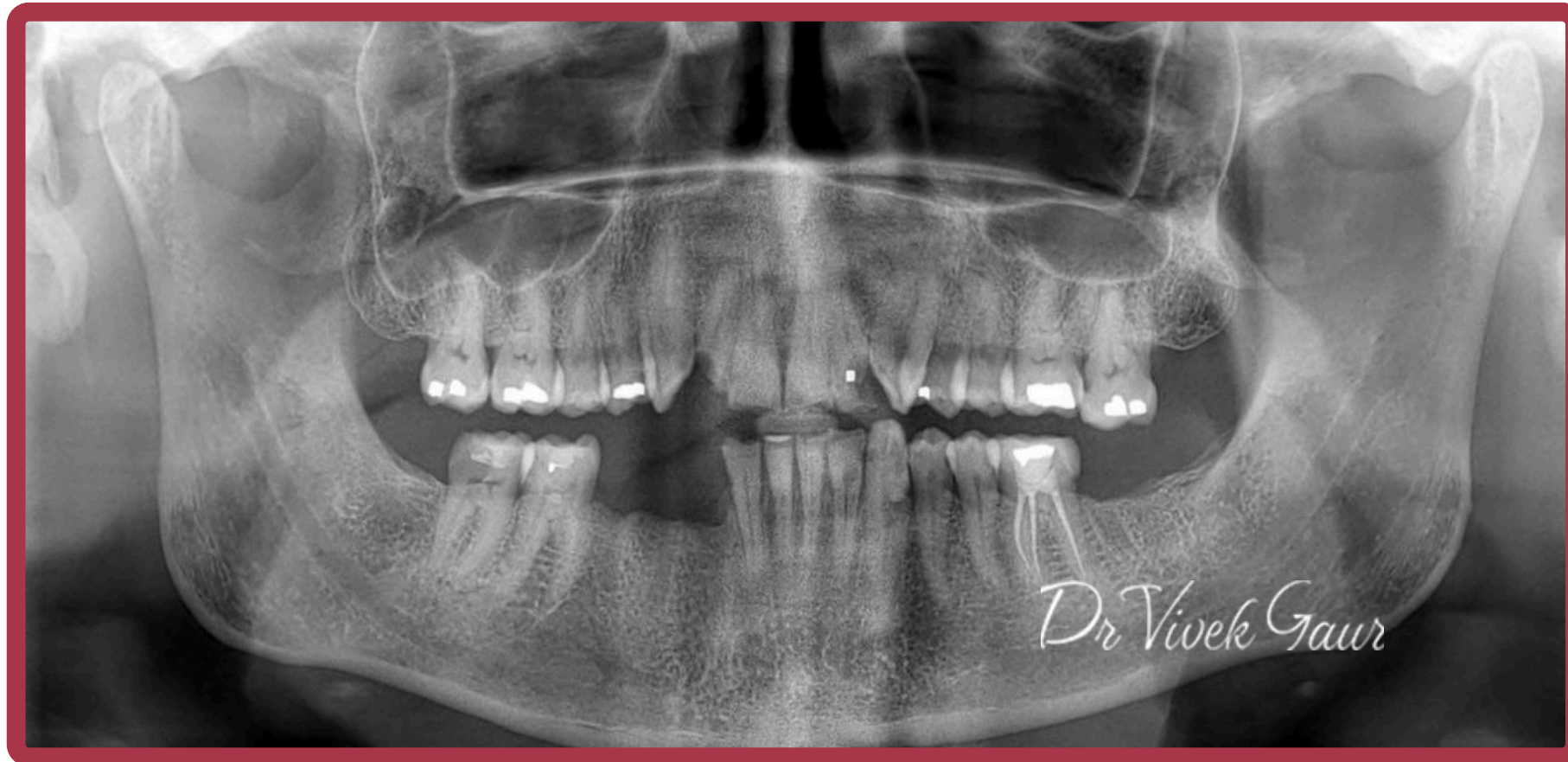Post-op XRAY



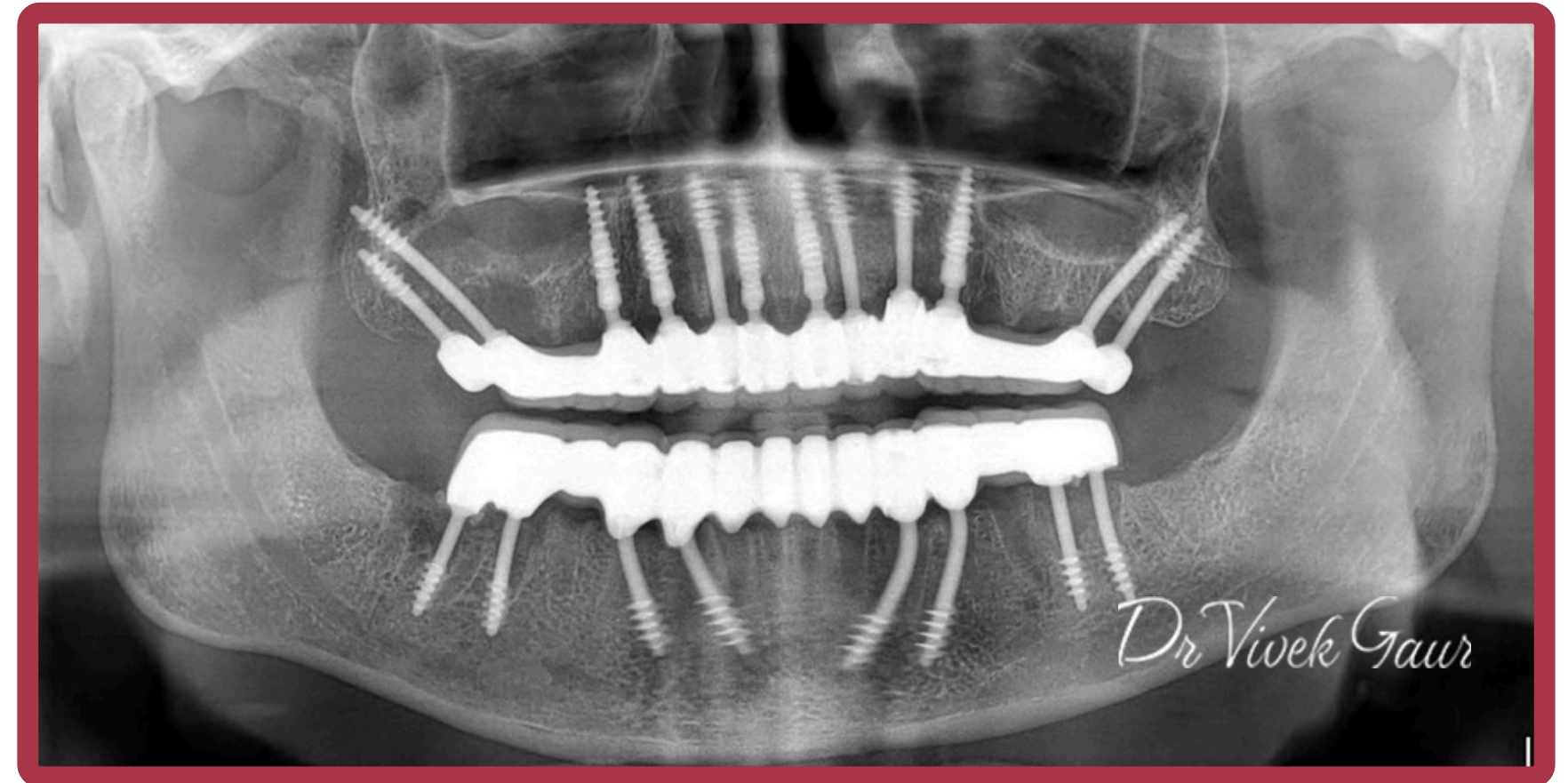
www.drivekgaur.com

Dr Vivek Gaur

Before

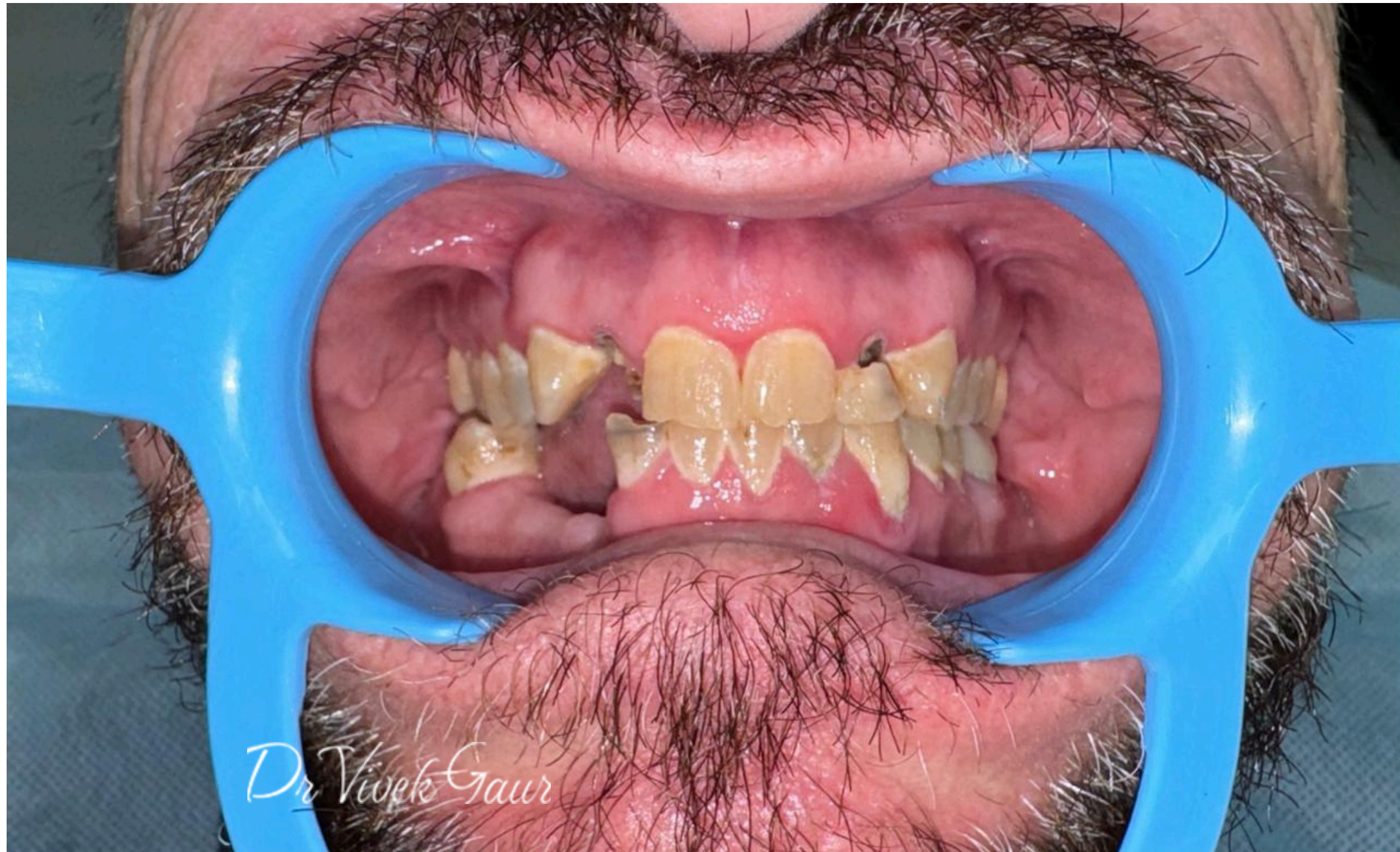

After



Dr Vivek Gaur

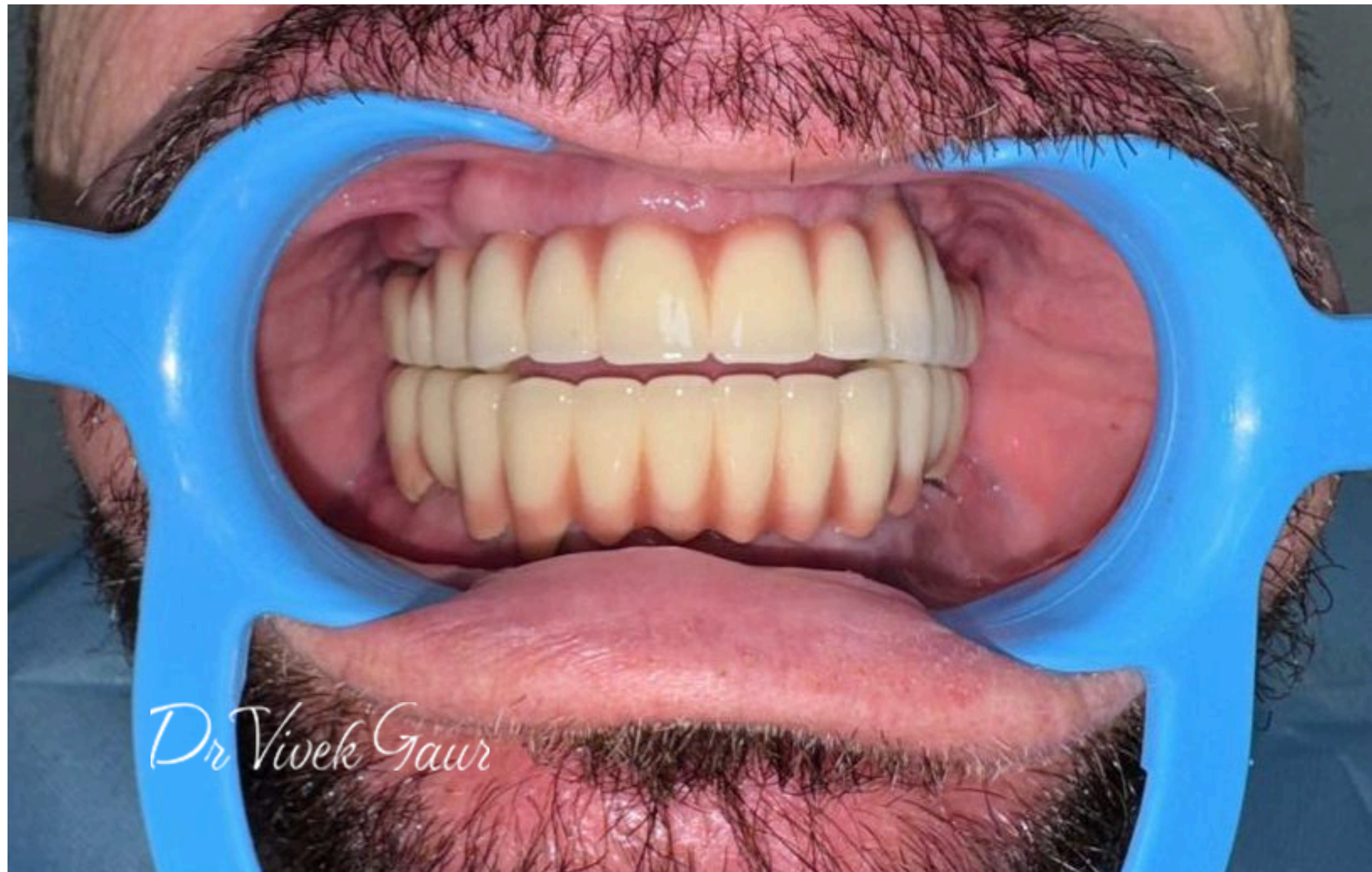Generalized Caries and Brittle Teeth



www.drivekgaur.com

Dr Vivek Gaur

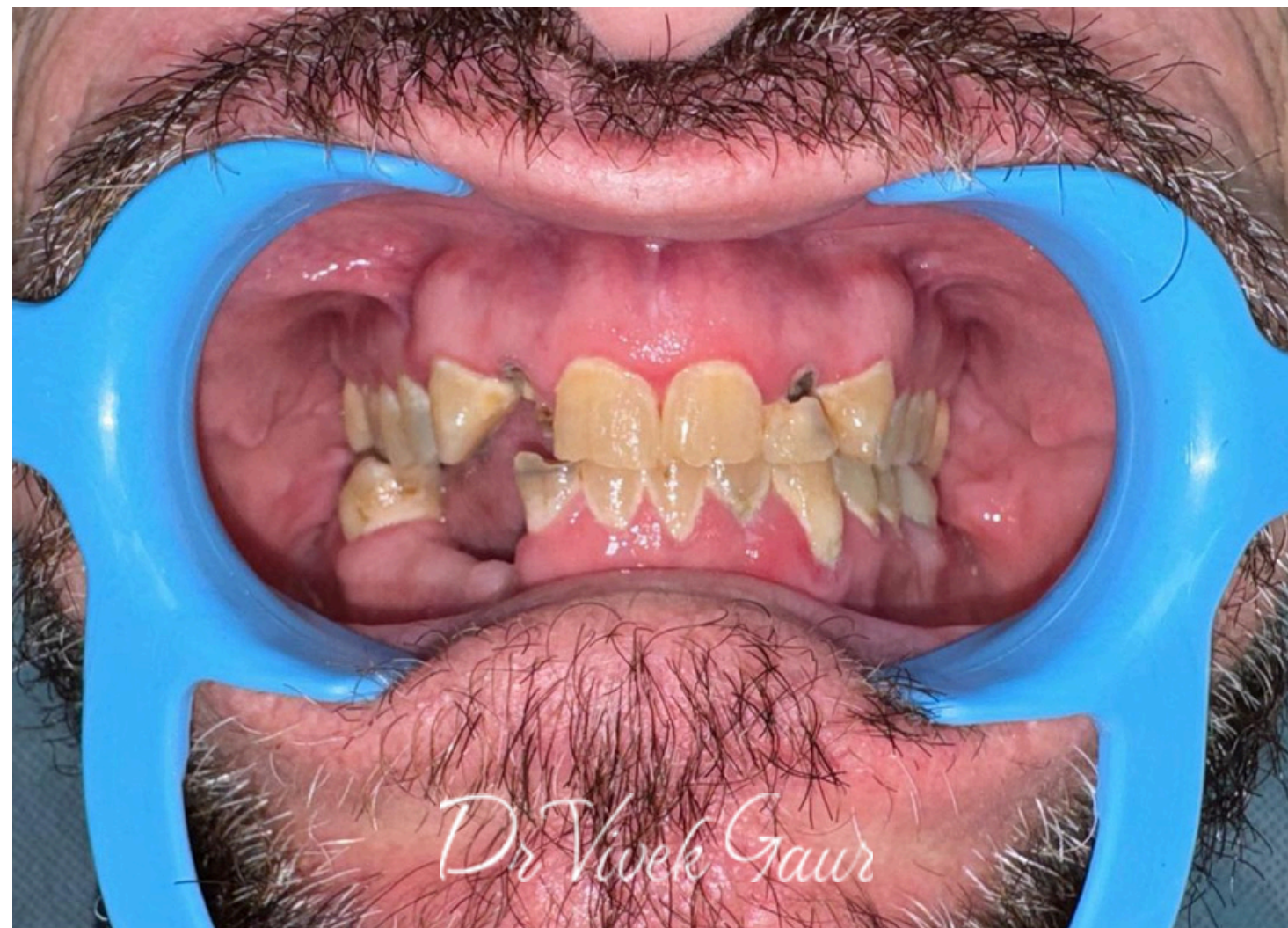**Final Prosthesis in 48 hours
with Full-Ceramic Restorations**



www.drivivekgaur.com

Dr Vivek Gaur

Before



After

