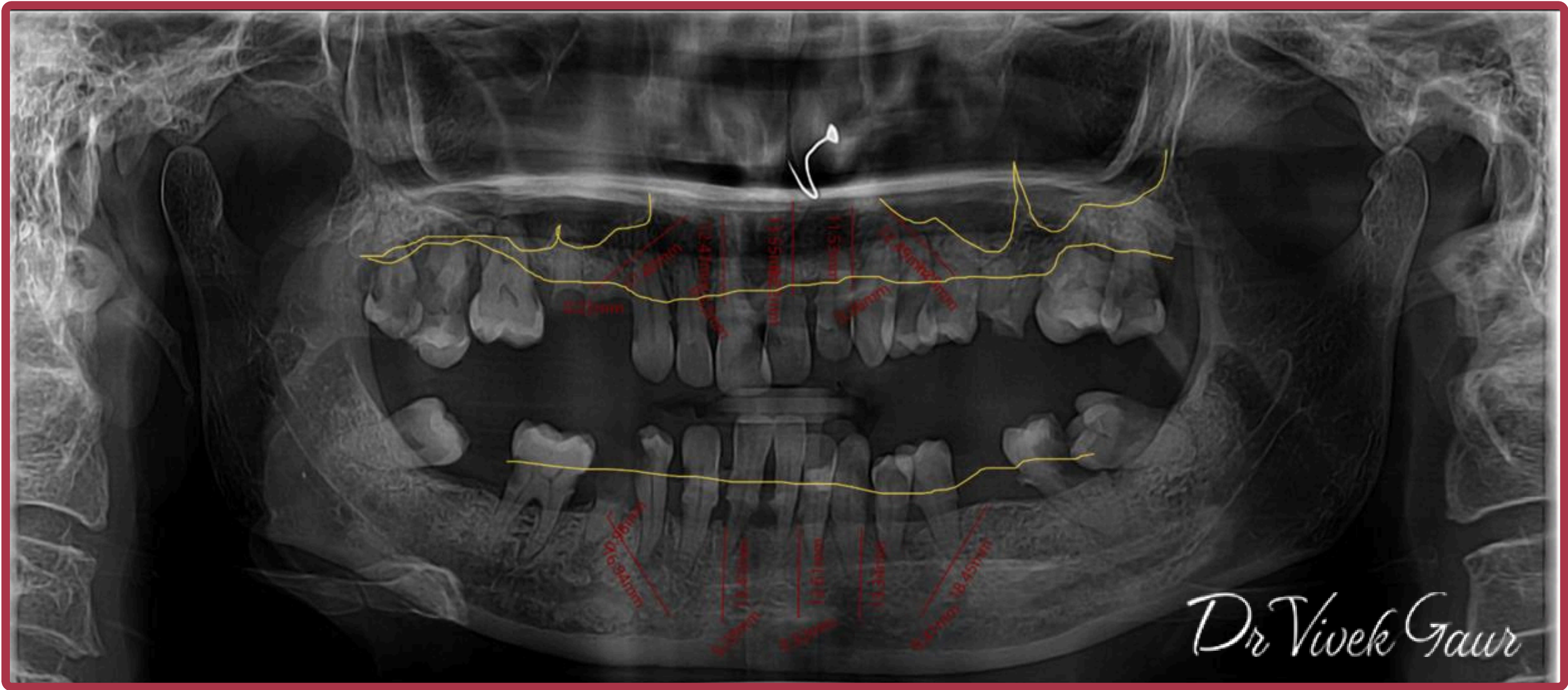


Multiple teeth affected by severe periodontal disease. Immediate **Corticobasal® Implants** placed after tooth extraction and infection removal. Upper jaw restored with ceramic prosthesis and lower jaw with graphene prosthesis for optimal function and aesthetics

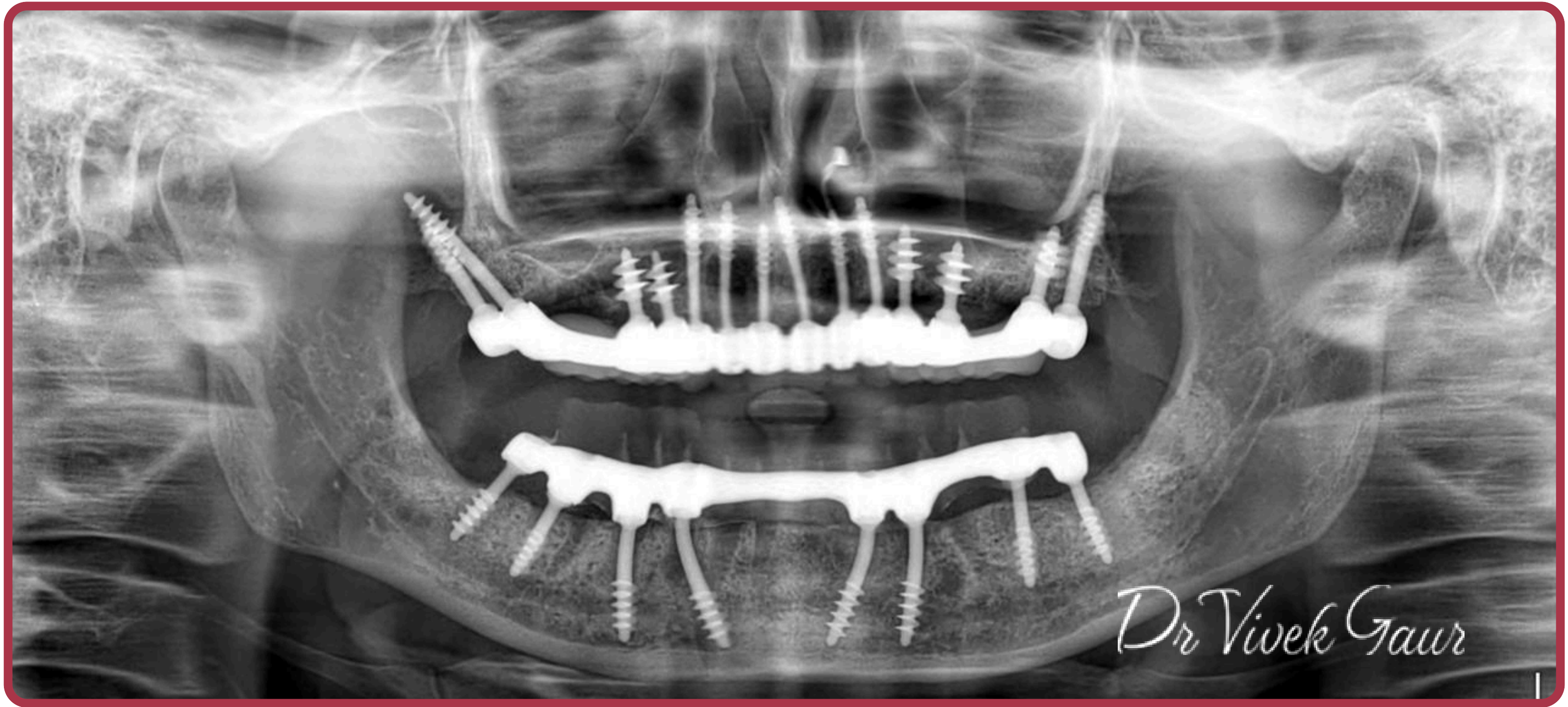Dr Vivek Gaur

Pre-op XRAY



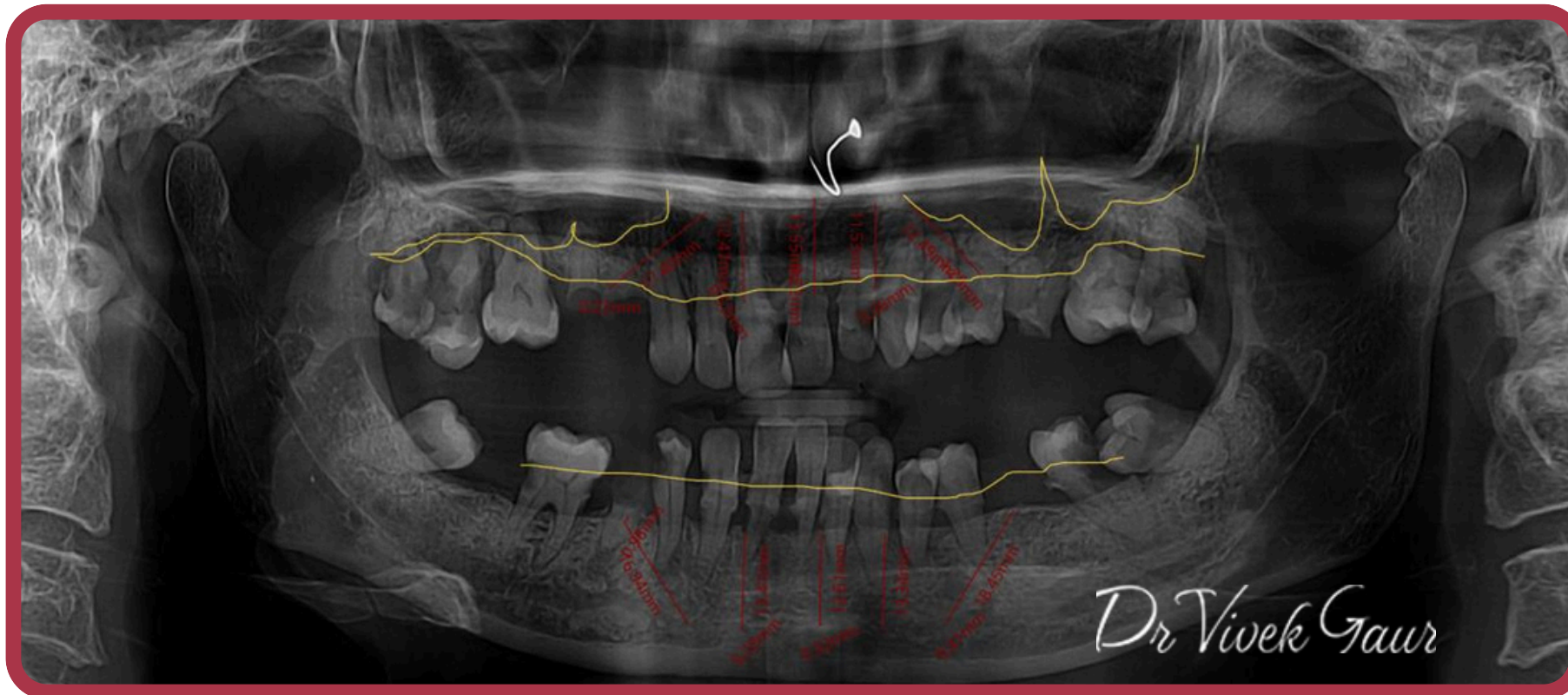
Dr Vivek Gaur

Post-op XRAY

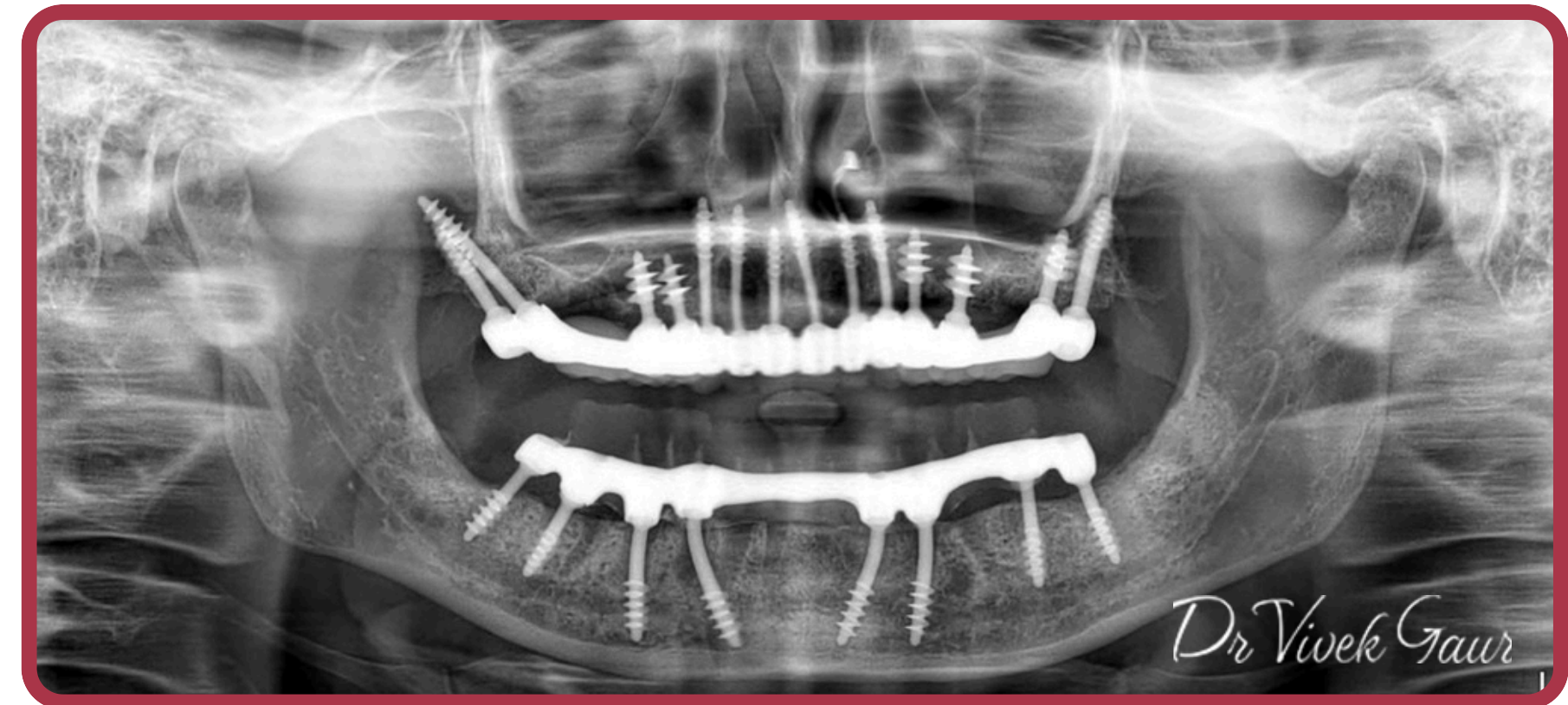

www.drivivekgaur.com

Before

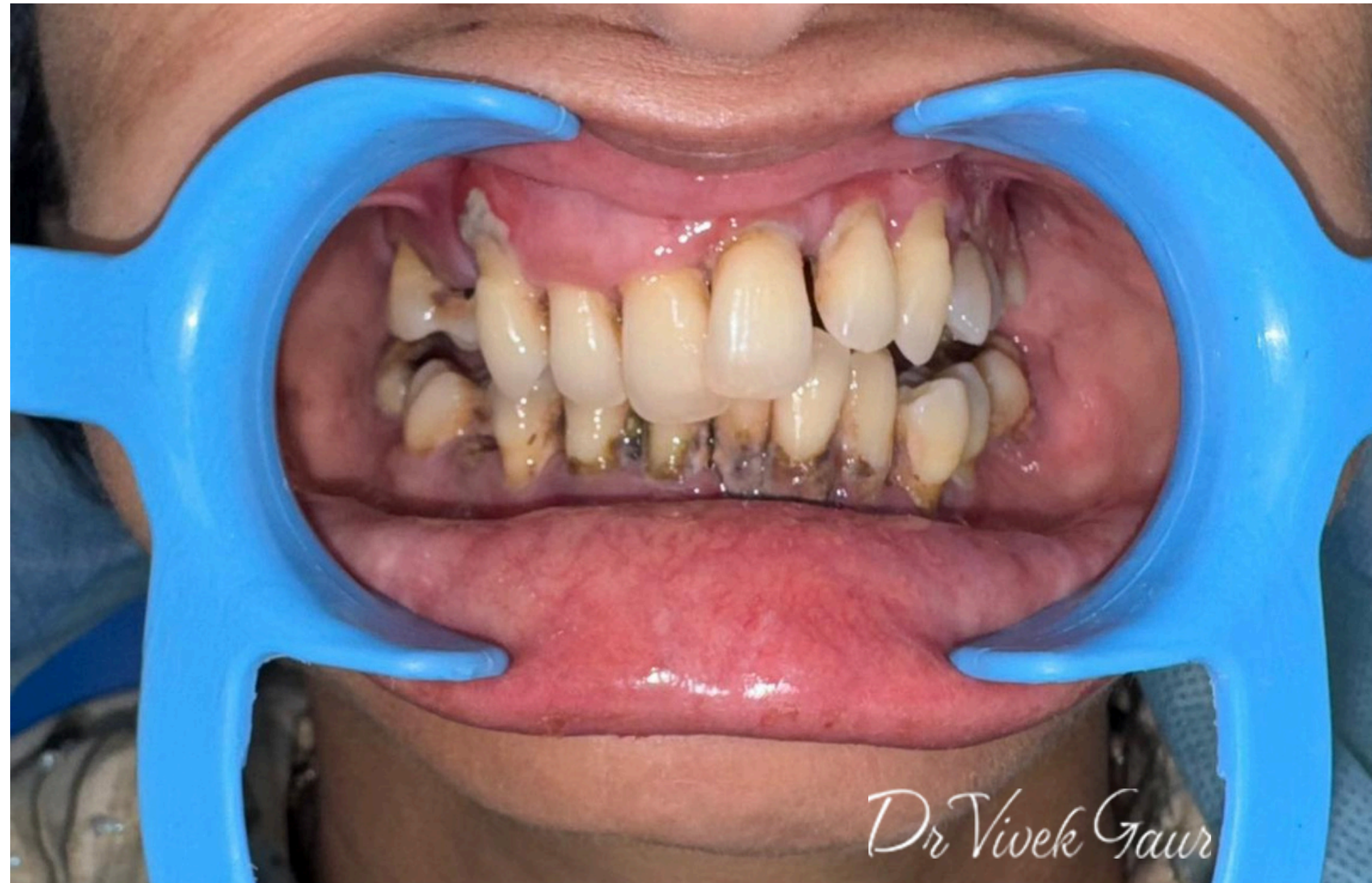

After



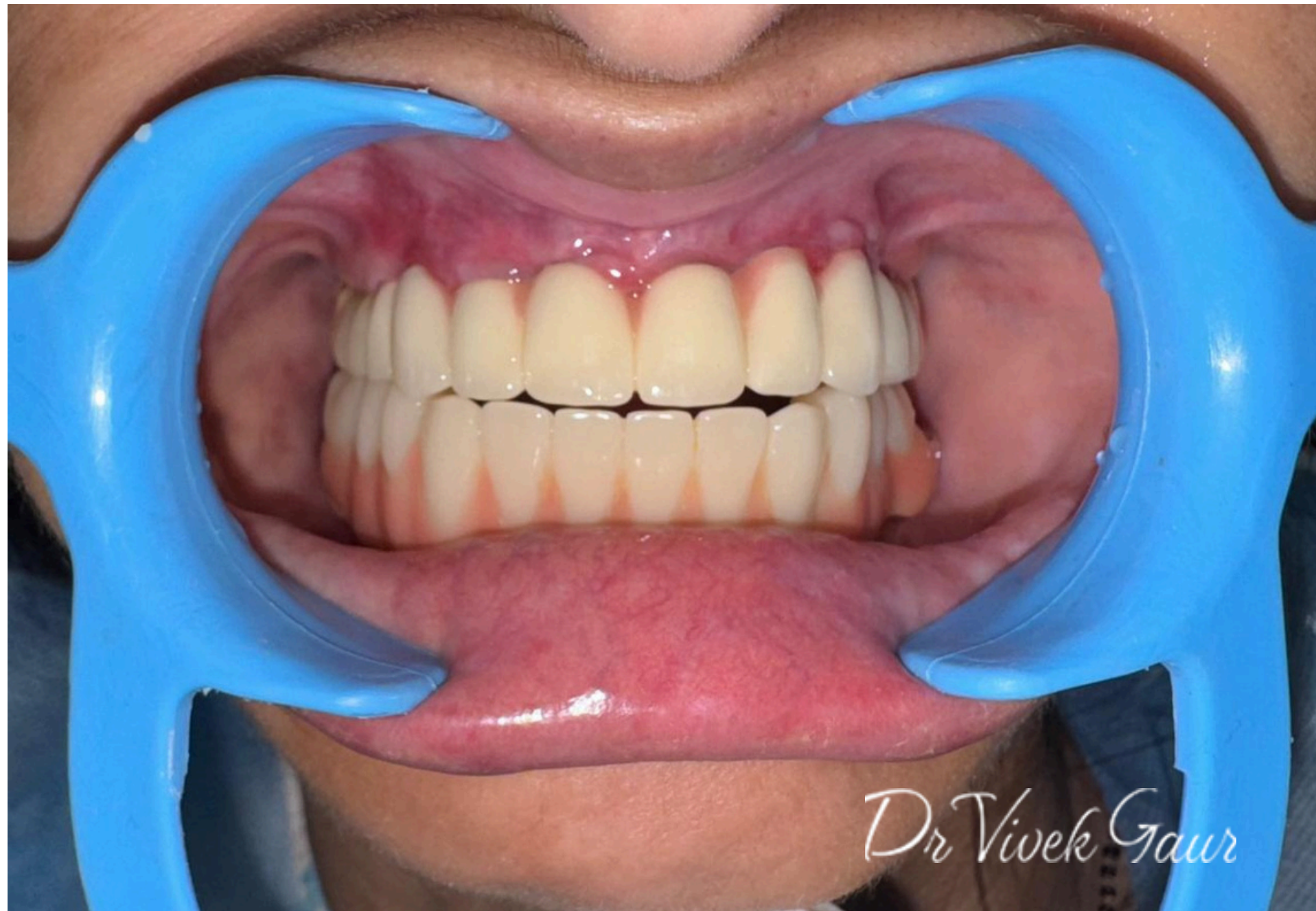Dr Vivek Gaur

**Multiple Teeth Affected By
Gum Disease**



Dr Vivek Gaur

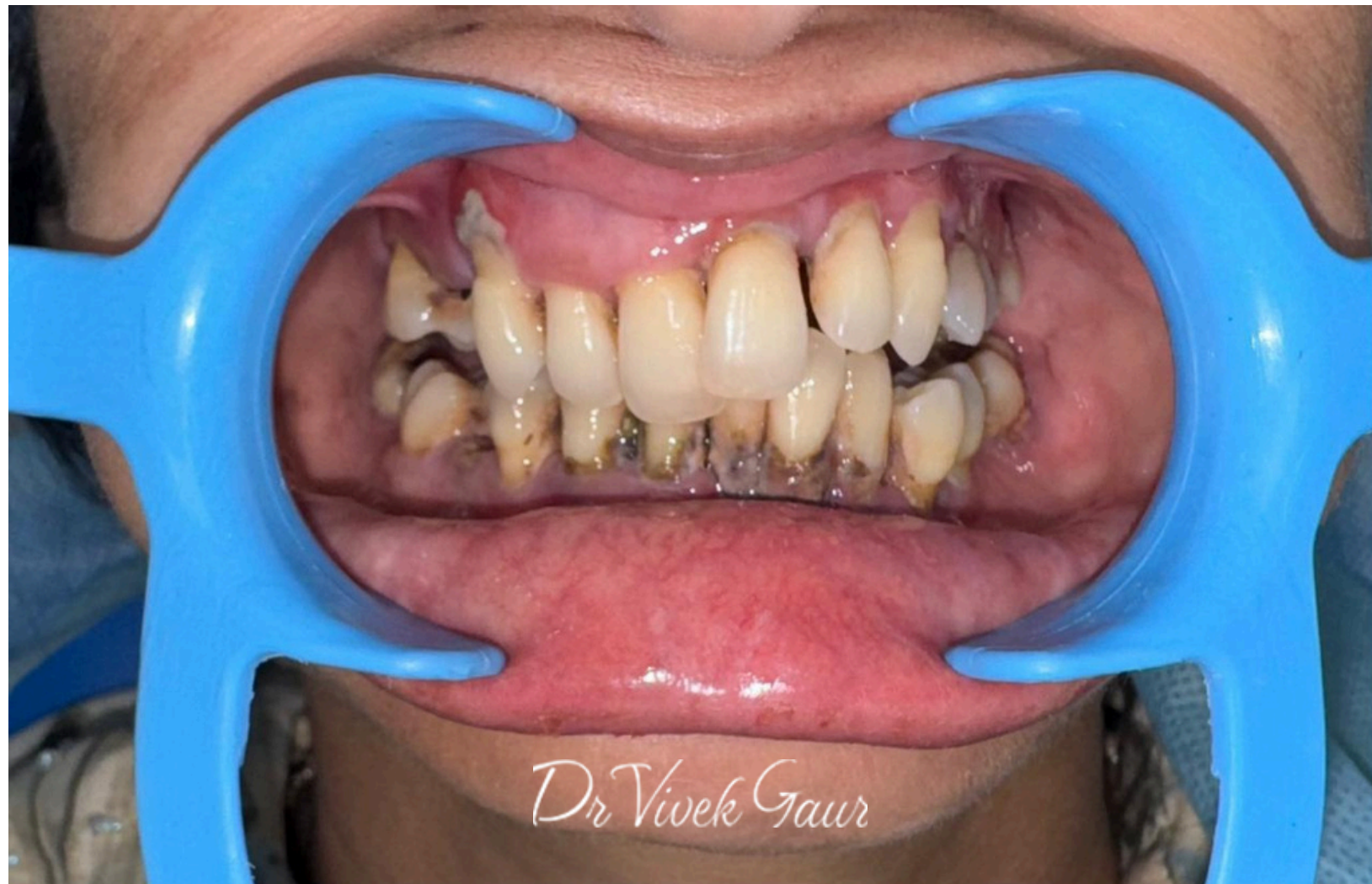Dr Vivek Gaur
Final Prosthesis



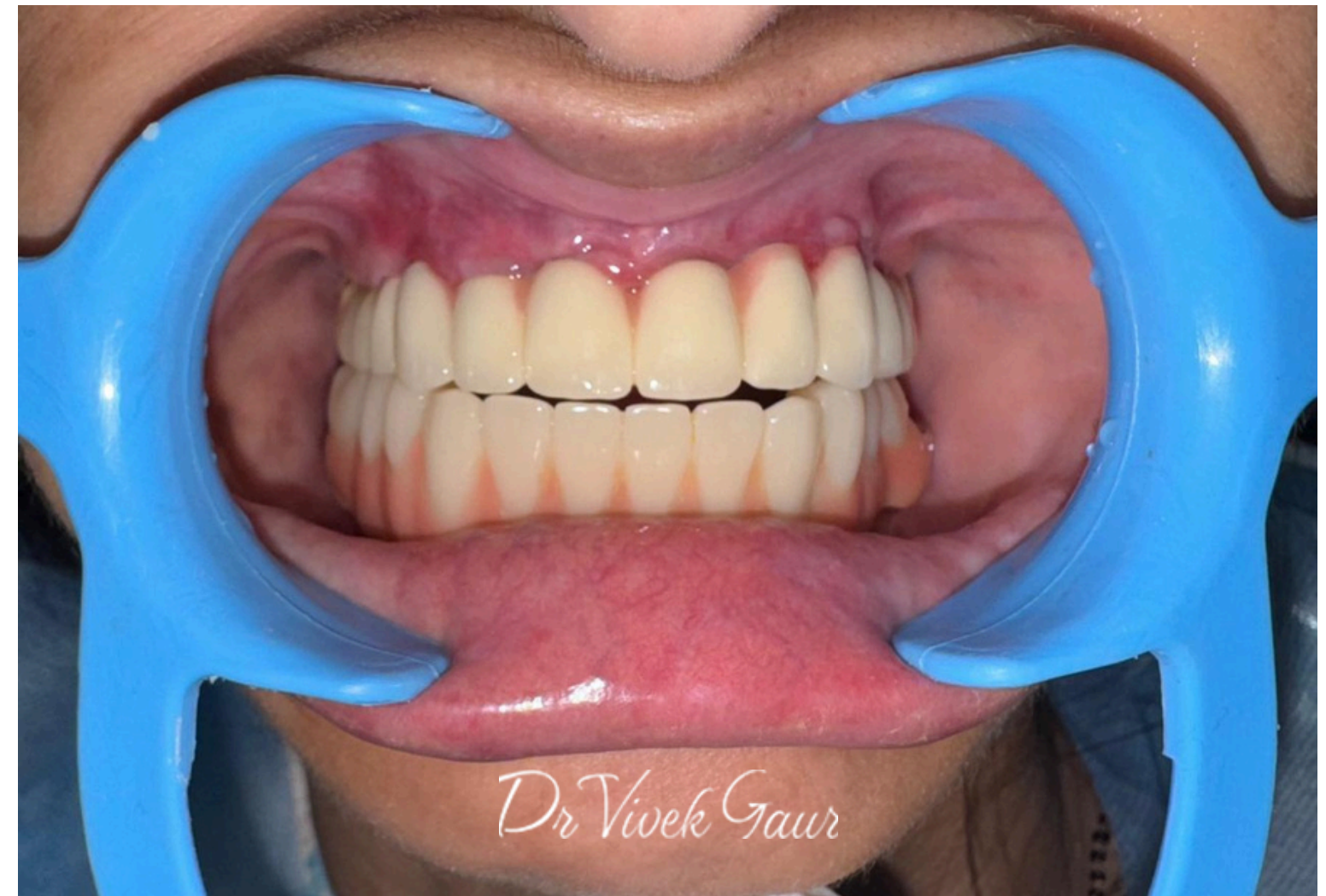Upper Jaw: Ceramic
Lower Jaw: GCam

Dr Vivek Gaur

Before



After



www.drivivekgaur.com